

# Creating effective dental flaps

*Practitioners can use this surgery to visualize and treat dental problems.*



By Beatriz Woodall,  
DVM  
Contributing Author

**T**he gingival flap technique, the most common periodontal surgery, raises gingival tissue so practitioners can access the underlying anatomy. Flaps offer a method to expose the root surface (*Figure 1A*, page 38) for dental procedures, such as:

- Facilitating deep periodontal pocket cleaning and root planing
- Freeing or extracting impacted or retained deciduous or adult teeth
- Repairing oronasal fistulas
- Retrieving retained tooth root remnants
- Surgically extracting difficult teeth, such as multi-rooted teeth; teeth with long roots, such as the canine teeth; or ankylosed teeth.

## Types of flap procedures

Flaps can be full or partial thickness. Full-thickness flaps are elevated by blunt dissection, which includes the periosteum, exposing bone at the surgical site. Partial-thickness flaps leave the periosteum attached and avoid deep vessels, such as

the palatine artery. These two methods can be combined in a single-flap procedure, such as a double flap to repair major oronasal fistulas.

This article will only focus on flaps that are used to expose the alveolar bone in preparation for extraction of the tooth or removal of a retained root. The reader is directed to any of the available veterinary dentistry references for information on gingival flaps that are used to treat and reverse periodontal disease.

## Basic instruments

Most flaps can be created with the following instruments:

- Size 11 or 15 scalpel blade with handle
- Periosteal elevator
- 3-0 to 5-0 absorbable sutures
- Needle holder
- Small scissors
- Small thumb forceps.

## Simple gingival flap technique

Practitioners can use a simple flap technique in their hospitals to improve the success of their dental procedures.

- **Gingival flaps are usually recommended when extracting canine teeth, premolars and molars.**
- **Flaps are not necessary when extracting incisors (unless visualization of the incisor's root is essential to the procedure).**

Before starting the flap, practitioners should perform appropriate nerve-blocking techniques (See *Dental nerve block techniques*, page 22).

Gingival flaps are typically recommended when extracting canine teeth (because of the long root), premolars and molars. Generally they are not necessary when extracting incisors unless visualization of the incisor's root is essential (*i.e.*, to visualize a retained or fractured root). With severe periodontal disease, the flap may not be necessary if the teeth are already mobile and have lost the majority of their periodontal attachment. However, the gingival flap is warranted to close the extraction site because it decreases pain and healing time for the patient. Many practitioners believe that extraction sites should be left open to drain when infection is present. Proper curettage of infected bone, complete removal of the root(s) and flushing of the socket will alleviate any need for drainage. Open sockets are prone to the accumulation of bacteria, hair and food.

Using a #11 or 15 scalpel blade, separate the gingival attachment from the tooth by inserting the blade between the gingiva and the tooth and then moving completely around the tooth in a circumferential motion. Once the gingival attachment is freed from the tooth, make two diverging incisions through the buccal gingiva overlying the alveolar bone and roots

of the tooth to be extracted (*Figure 1B*, page 38). The base of the flap (pedicle) should be broader than the free edge to ensure better vascularization. Care should be taken when creating the diverging incisions to avoid the nerves described previously in the dental nerve block article (*Dental nerve block techniques*, page 22) and other structures, such as blood vessels and salivary ducts.

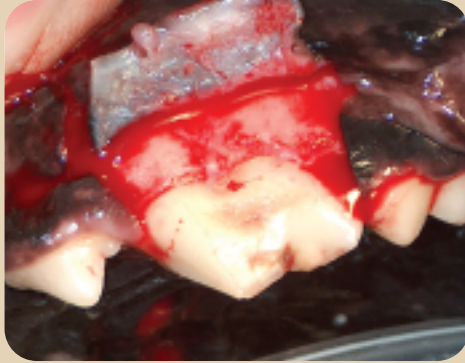Using a periosteal elevator, separate the gingiva and mucosa from the underlying bone (*Figure 1C*, page 38). Patience and gentle tissue handling while elevating the gingiva will avoid damaging or puncturing the flap with the sharp instruments.

Retract the flap and expose the buccal alveolar bone. Using a small round bur, with irrigation, remove one-third to one-half of the buccal bone to expose the root(s) of interest. If extracting a multi-rooted tooth, the buccal bone should be removed to at least expose the bifurcation for sectioning of the tooth into single-rooted pieces. Once adequate exposure has been created, the tooth can be extracted (See *Techniques for dental extractions*, page 43).

After the tooth is extracted, the alveolar bone has been smoothed to remove any sharp edges (*Figures 1D* and *1E*, page 38) and the area has been irrigated to remove any debris, reposition the flap. If there will be tension on the flap, the flap can be undermined at the base (much as you

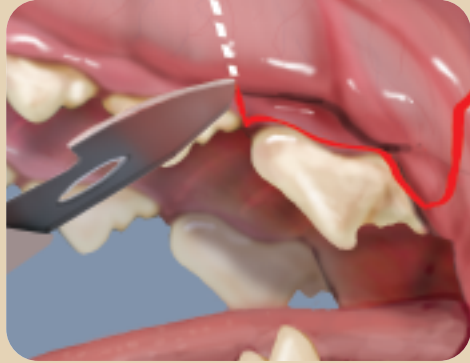
### Figure 1: Simple gingival flap technique

Figure 1A



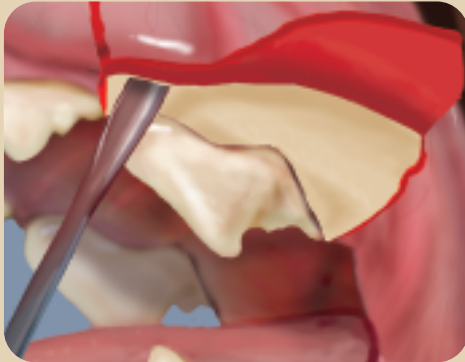
Example of a gingival flap to expose the alveolar bone overlying the tooth roots.

Figure 1B



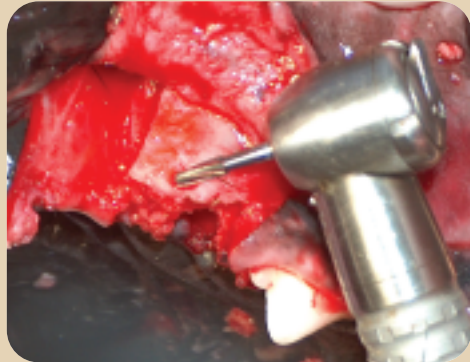
Make two diverging incisions through the gingiva overlying the alveolar bone and tooth roots.

Figure 1C



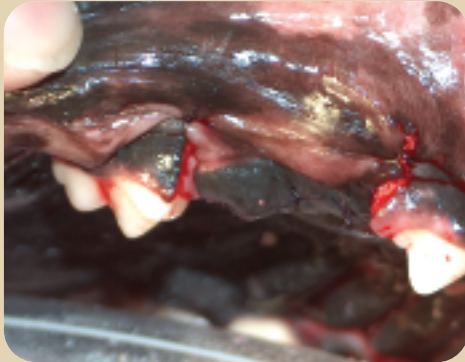
A periosteal elevator is used to expose the alveolar bone.

Figure 1D



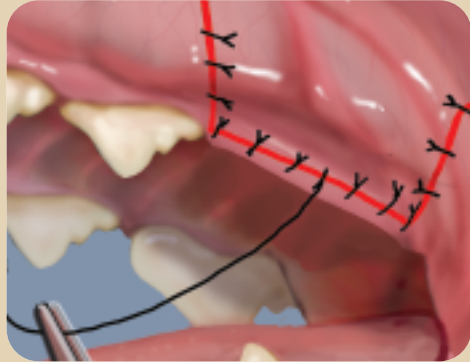
Smooth the alveolar bone.

Figure 1E



The gingiva is laid back in normal position for suture placement.

Figure 1F



The sutured flap should cover the defect without tension. Place as few sutures as possible to hold the flap in place.

would do when undermining skin) to release the tension. Then place a couple of sutures on the edges (3-0 to 5-0 absorbable suture) and again make sure there is no tension. (If there is still tension, undermine the flap until there is none.) Then place as few sutures as possible to hold the flap in place (*Figure 1F*, page 38). Using a small number of sutures will allow for better blood flow and decrease the chance of tissue devitalization. Suture tails can be cut short because suture removal is not necessary since absorbable suture material should have been used and the sutures will dissolve in the moist oral environment.

Last, with a moist gauze sponge, apply light pressure for a few minutes (minimum of 60 seconds) over the flap area to facilitate initial adhesion and decrease hemorrhage and hematoma formation.

**Oral antibiotics should be used before and after surgery to reduce the chance for bacteremia secondary to many dental procedures.**

### Postsurgical care

The most important element of postsurgical care is client education. Before the patient goes home, discuss with the owners the warning signs Pets may exhibit that would indicate problems, such as drooling, pawing or rubbing at the mouth or increased swelling in the mouth or facial area. Explain to clients that it is important to bring the Pet back to the hospital immediately to address these issues. Communicate the following recommendations to clients before they leave the hospital:

- Only offer soft food for one week.
- Return to home oral hygiene after the

one- to two-week recheck.

- Offer hard chews and a dental diet after the recheck, if approved by the veterinarian.

Oral antibiotics should be used before and after surgery to reduce the chance for bacteremia secondary to many dental procedures. My preference is clindamycin (5-11 mg/kg orally twice daily) or amoxicillin-clavulanate (13.75 mg/kg orally twice daily) started three days before the procedure until the seven- to 14-day recheck. The length of antibiotic administration might be shortened (*e.g.*, three days prior and five days post-procedure) in less severe cases.


The American Veterinary Dental College recommends the use of antibiotics in patients with evidence of underlying systemic diseases, such as cardiac, hepatic and renal diseases; immunocompromised patients; and/or those with severe oral infection. Healthy patients may be able to fight the bacteremia, but the majority of veterinary dental patients do not present as healthy patients.

### Complications

The most common complications include:

- Infection
- Necrosis of tissue caused by improper suture placement (too tight or closely spaced)
- Suture dehiscence

### Conclusion

For many veterinarians, the thought of attempting a flap might be overwhelming. However, with appropriate instruments, a bit of practice and patience, it will become a rewarding tool that helps ensure all of your patients with dental problems have a healthy mouth. 

**Beatriz Woodall, DVM**, received her veterinary degree from the Federal University of Rio de Janeiro, Brazil, in 1991. She completed an internship in equine internal medicine and surgery at Louisiana State University in Baton Rouge and was a visiting professor in anesthesiology from 1994 to 1996 at the University of Illinois where she completed her Educational Commission for Foreign Veterinary Graduates rotations. Dr. Woodall worked at the Pontchartrain Animal Hospital in Slidell, La., where she focused on building the practice's dental business and helping the clinic recover from Hurricane Katrina. Dr. Woodall joined Banfield in October 2007 as an Associate Doctor in the Cincinnati, Ohio area, where she resides with her husband, two children and two dogs (a Chocolate Labrador and a Yorkie).

### Additional reading

1. Auvil J, DVM, DAVDC. Grady Veterinary Hospital. Cincinnati, OH. Personal communication, January 2008.
2. Bellows J. *Small animal dental equipment, materials and techniques*. Ames, Iowa: Blackwell Publishing, 2004.
3. Hale F. Extraction. In: *Understanding veterinary dentistry*. Available online at: [www.vin.com](http://www.vin.com). Accessed Jan. 30, 2008.
4. Harvey C, Emily P. *Small animal dentistry*. St Louis, Mo.: Mosby Year Book Inc., 1993.
5. Holmstrom S, Frost P, Gammon R. *Veterinary dental techniques*. Philadelphia, Pa.: WB Saunders Co, 1992.
6. Levin J. Periodontal flaps and oronasal fistulas, in *Proceedings*. 12th Annu Vet Dental Forum 1998.
7. Use of antibiotics in veterinary medicine. American Veterinary Dental College. Available at: [www.avdc.org](http://www.avdc.org). Accessed Jan. 31, 2008.